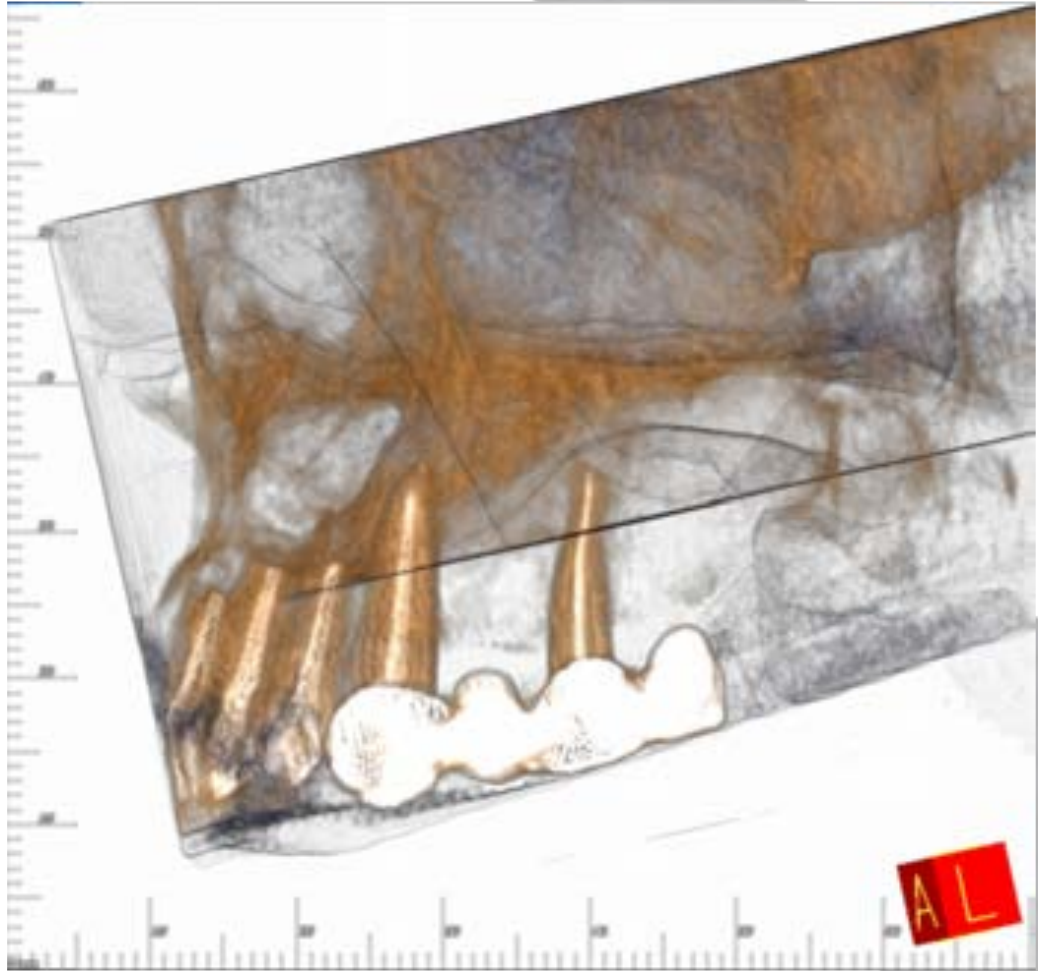
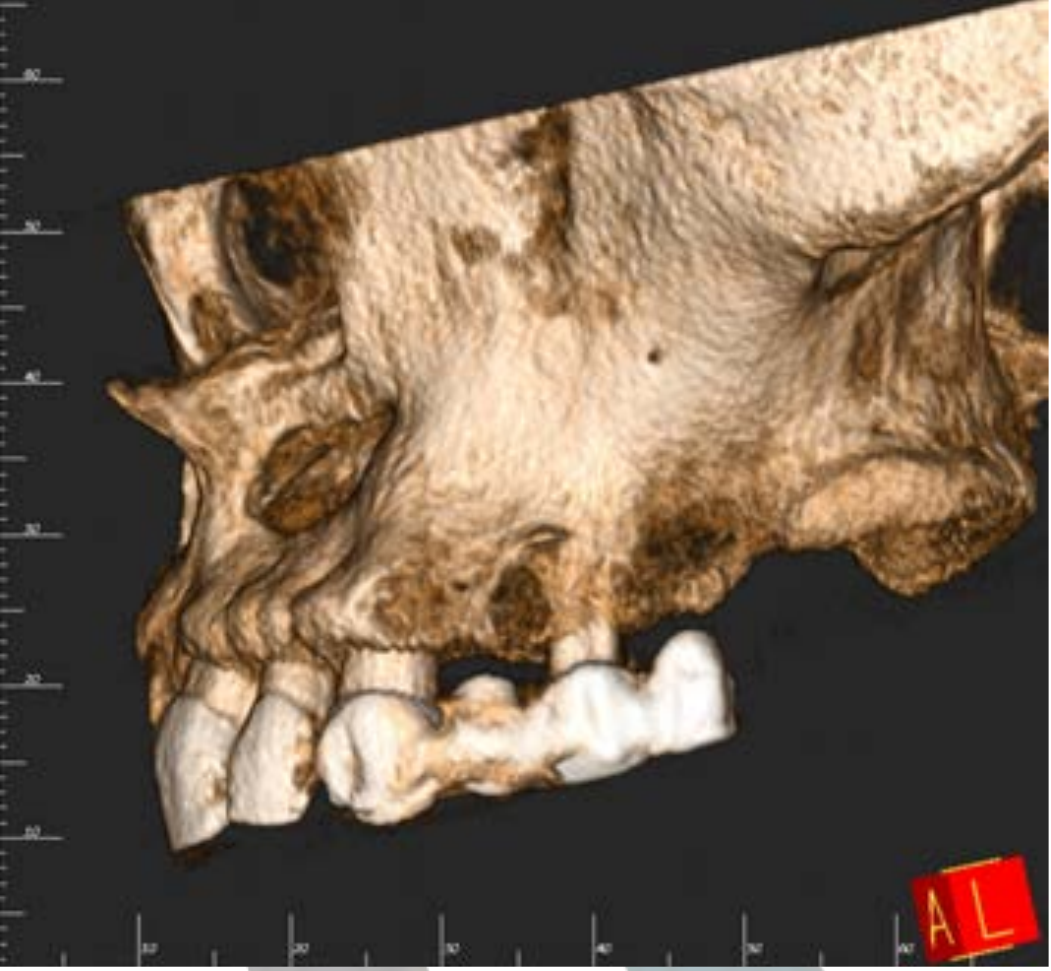
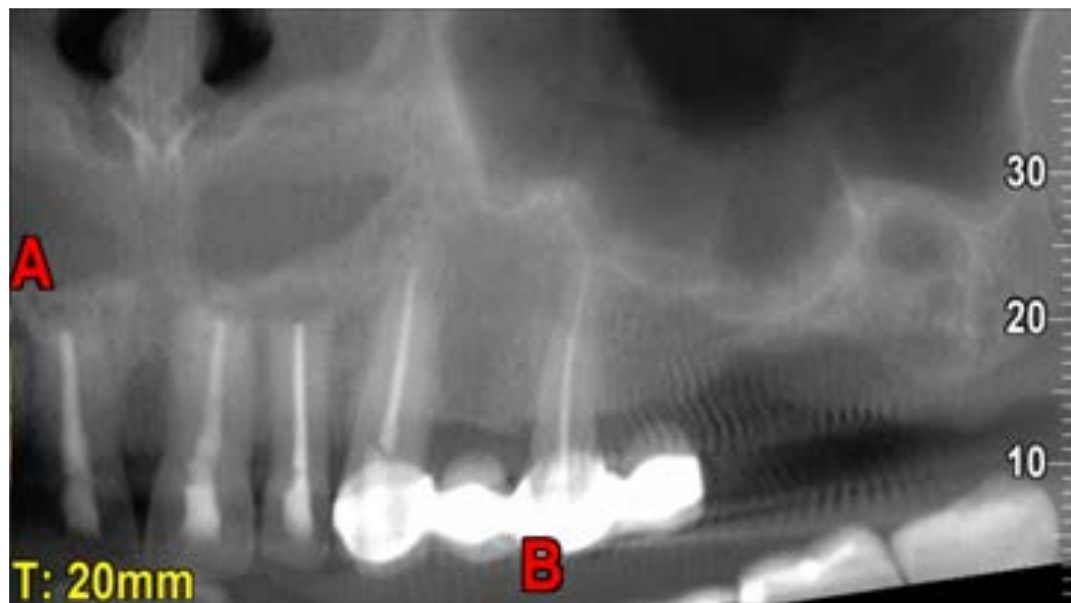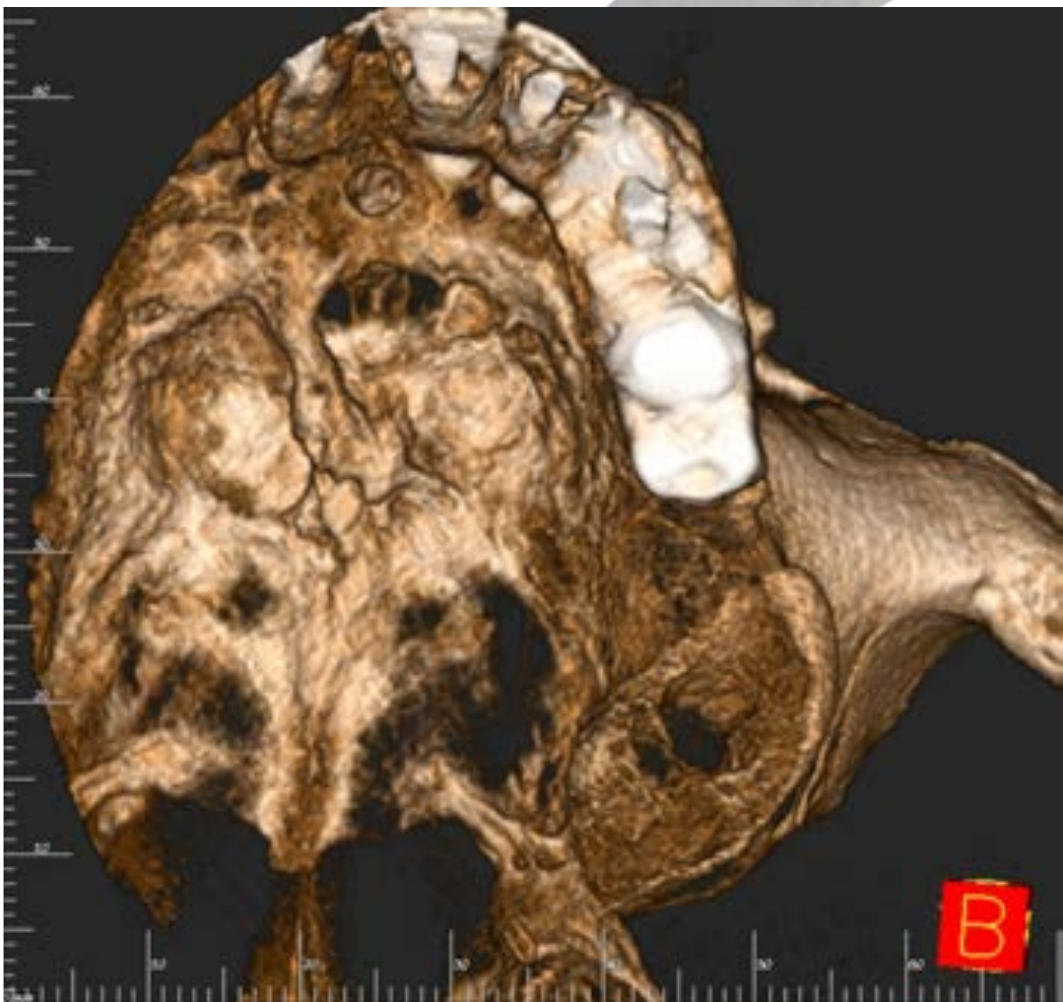
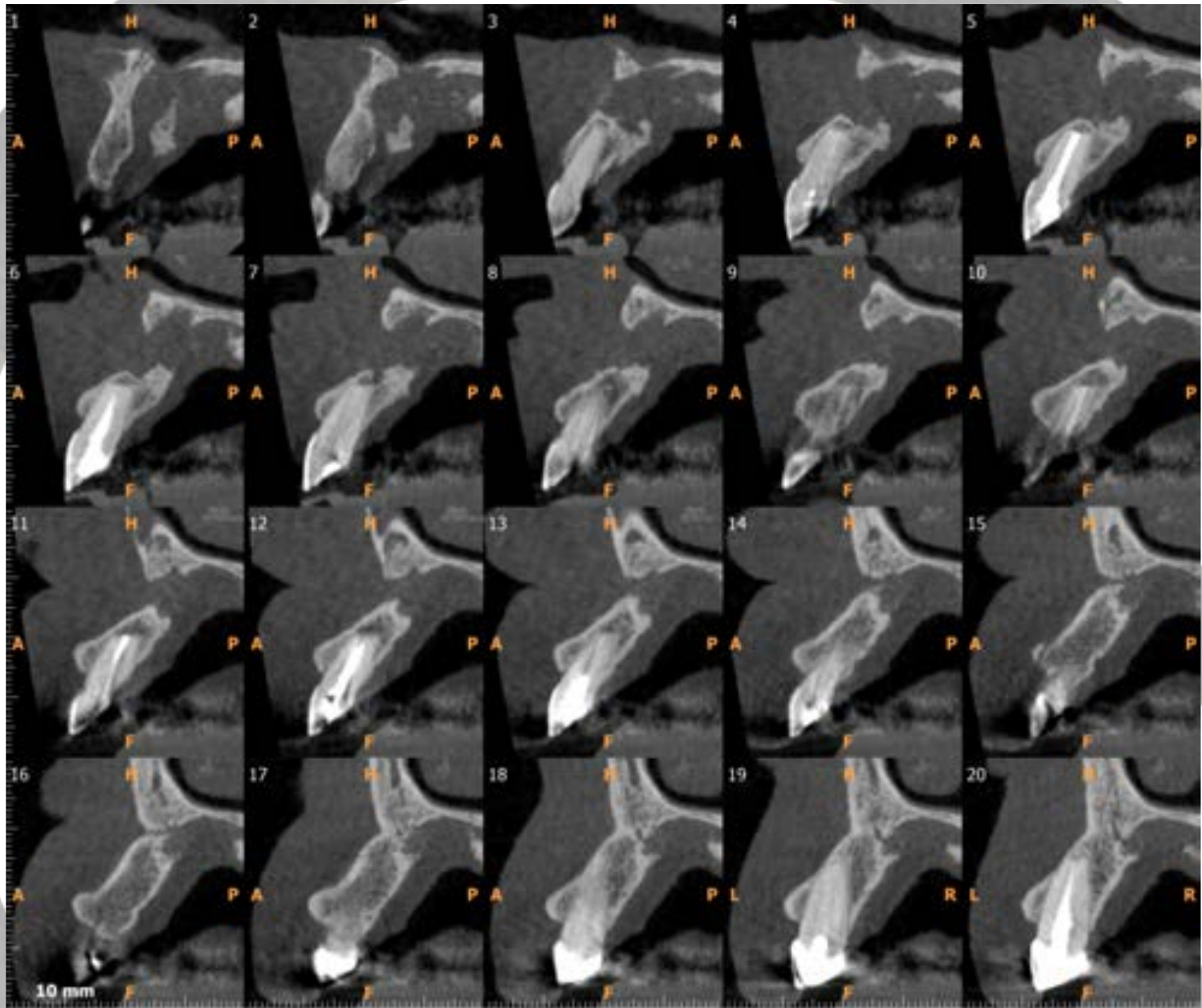
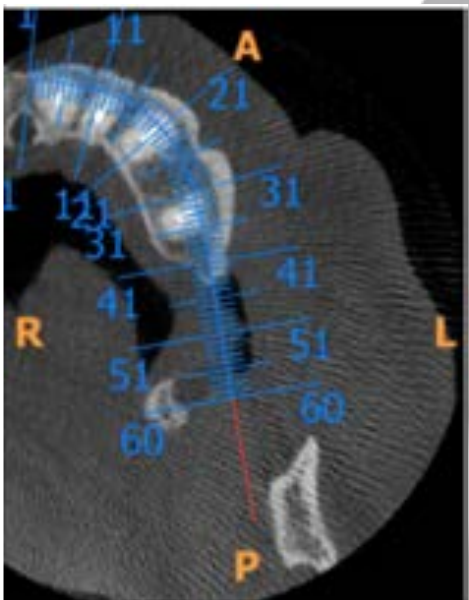
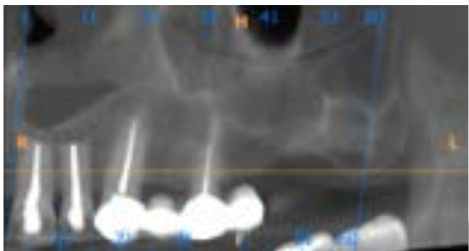
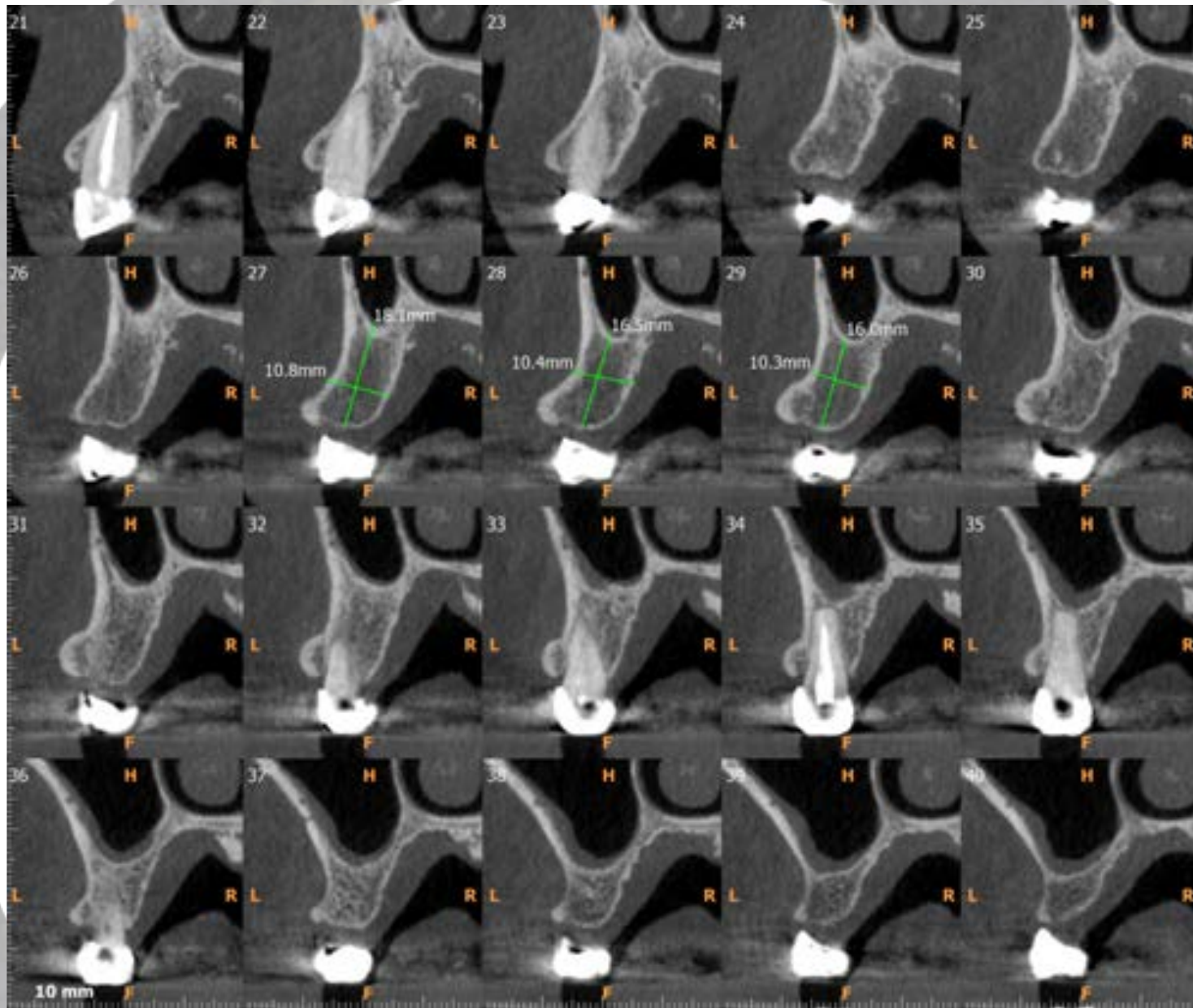
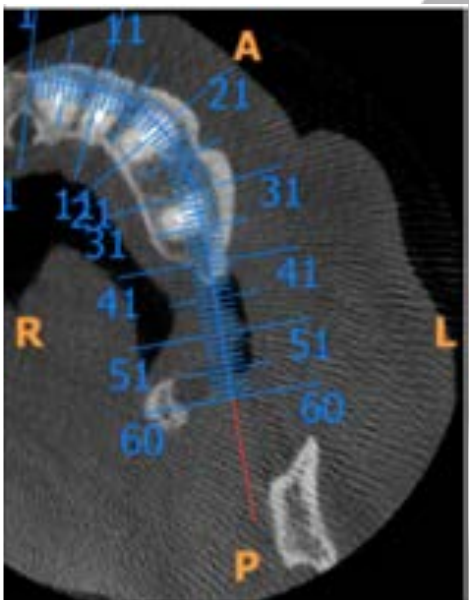
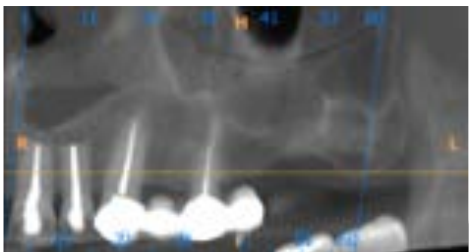


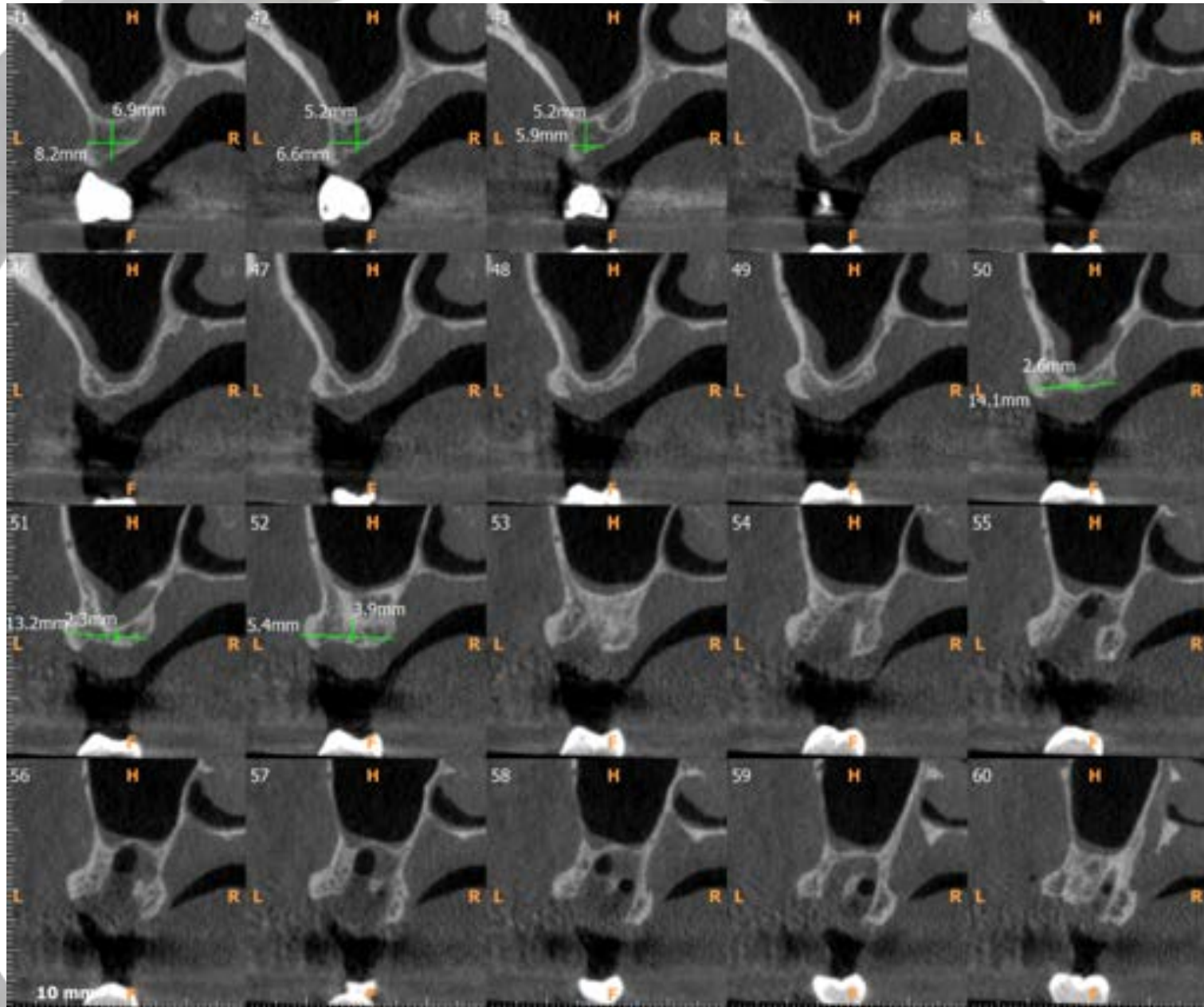
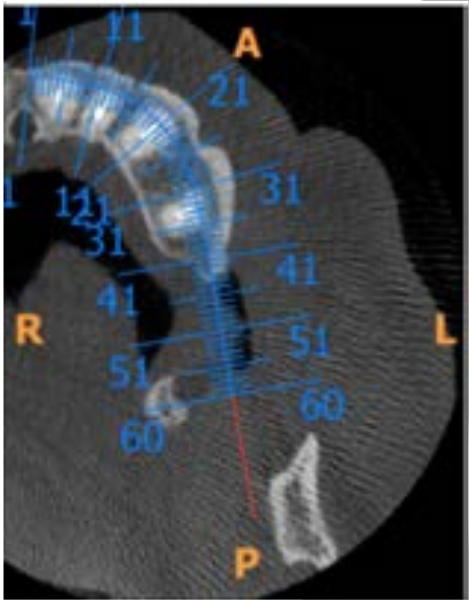
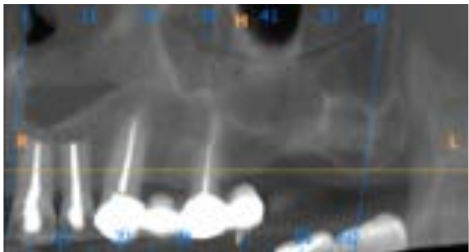
Caso Clínico
Lesión ósea maxilar
Dra. Araceli Martínez Miravé
Barcelona, Enero 2019

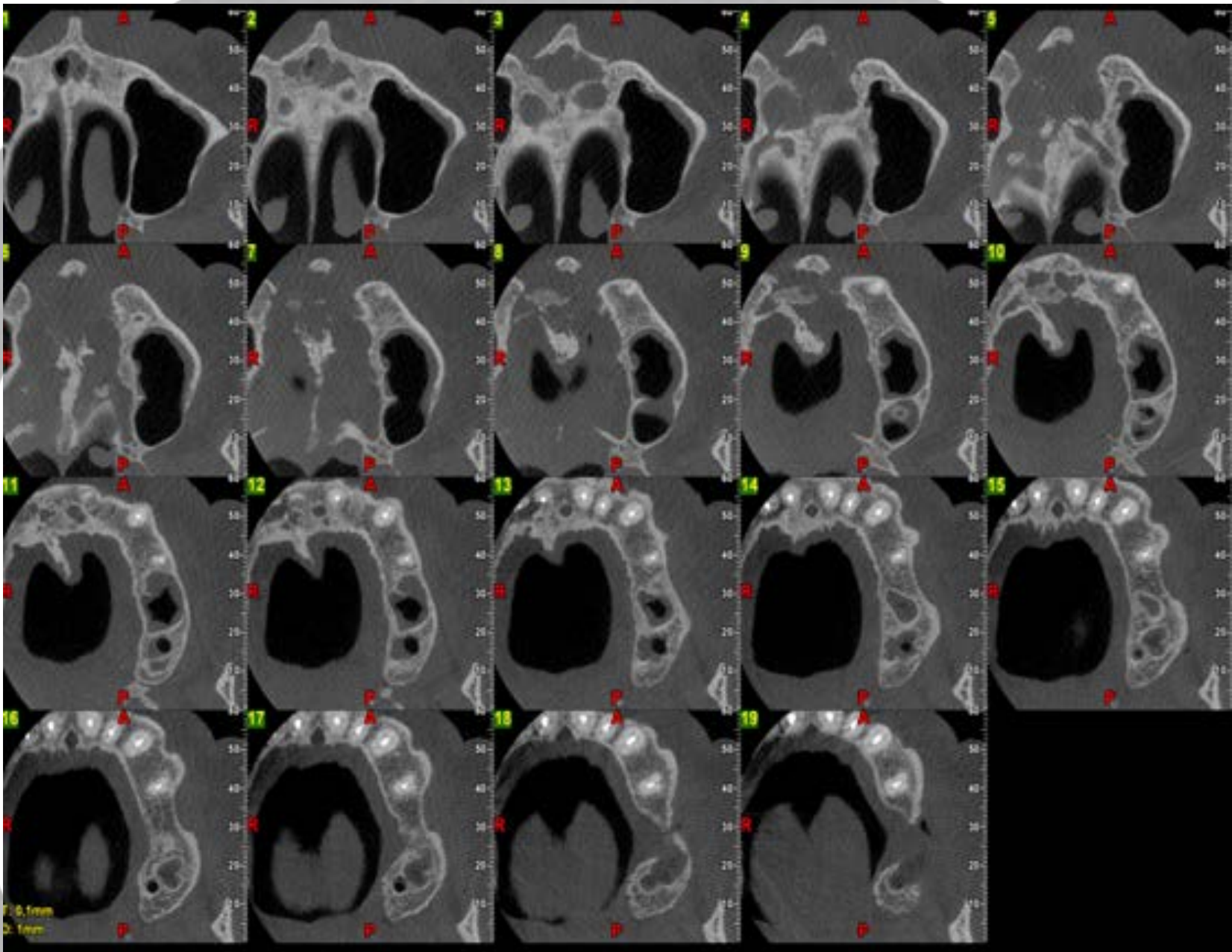
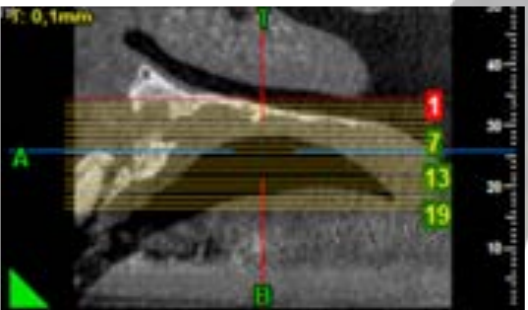
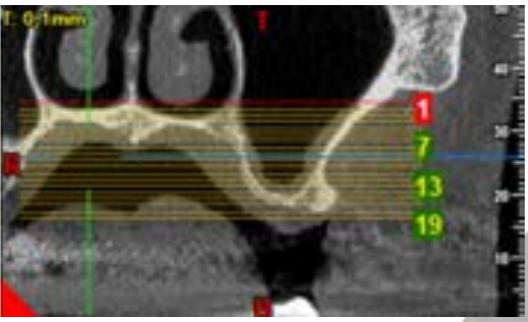


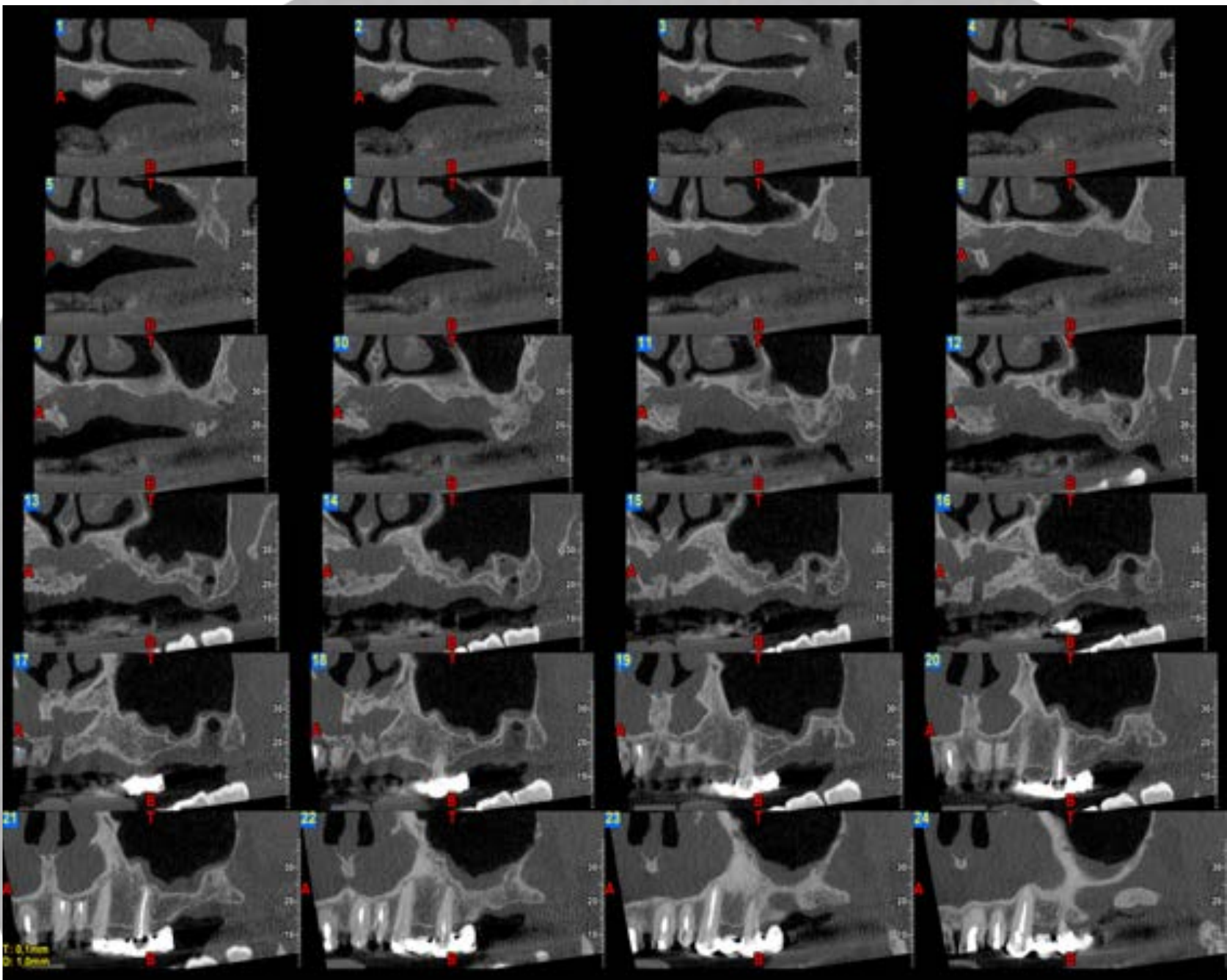
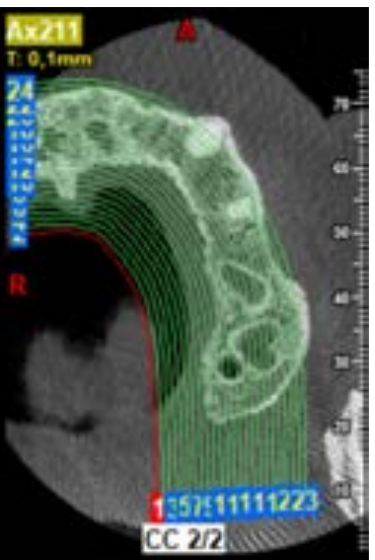












Conclusiones

En el sector anterior maxilar izquierdo se observa lesión ósea en el proceso alveolar, apical a las raíces de los incisivos 21 y 22, con discontinuidad en las corticales vestibular y palatina que genera comunicación buco-palatal (cortes ortorradales 3-16). Las características radiográficas de la lesión son compatibles con lesión cicatricial.